

# Ovarian aspergilloma in an immunocompetent patient masquerading as ovarian neoplasm

Gyanendra Singh, Anurag Singh\*, Anuragani Verma, Yogendra Verma, Neeraj Kumar

King George's Medical University, Lucknow, India.

\*Correspondence: Anurag Singh, King George's Medical University, Shah Mina Rd, Chowk, Lucknow, Uttar Pradesh 226003, India. Email: anugsvm@yahoo.com

How to cite this article: Singh G, Singh A, Verma A, et al. Ovarian Aspergilloma in an immunocompetent patient masquerading as ovarian neoplasm. Arch Clin Cases. 2023; 10(1):39-41. doi: 10.22551/2023.38.1001.10237

## ABSTRACT

Aspergillus is a ubiquitous fungus that can cause a variety of clinical syndromes. It can lead to a spectrum of clinical presentations depending upon the severity of the disease, degree of immune compromise, nature and intensity of inflammatory host response. Ovarian aspergilloma is extremely unusual, only a few case reports have been described in the literature. Here, we report a case of ovarian aspergilloma which was masquerading as ovarian neoplasm on clinical examination and radiology. To the best of our knowledge, this is the first case report of isolated ovarian aspergillosis in an immunocompetent patient.

**KEYWORDS:** Aspergillus; Ovary; Neoplasm; Fungal infection

## INTRODUCTION

Fungal infections are quite common in immunocompromised patients. Aspergillus is the most common, non-invasive type of fungal infection producing a wide range of clinical symptoms which are often extremely fatal. The clinical manifestations of the disease are diverse and depend upon the severity of the disease, degree of immune compromise in patients, and nature and intensity of the host immune response. Aspergillus primarily infects the respiratory passages, sinuses and skin of immunocompromised patients [1-3]. Because of varying clinical manifestations, often of a severe nature-Aspergillosis remains a major cause of patient morbidity and is responsible for more than one million mortalities in immunocompromised populations worldwide, annually [4]. The central nervous system and cardiovascular system may be affected by the direct or hematogenous spread of Aspergillus fungal elements [5-7]. Aspergillosis of the ovary is extremely rare, only a few case studies are reported in the literature [8,9]. Here, we report a case of ovarian Aspergillosis which was masquerading as ovarian neoplasm on clinical examination and radiology. The aim of this case study is to bring to light an unanticipated site of Aspergillus infection that is clinically mistaken for ovarian tumors. To the best of our knowledge, this is the first case of isolated ovarian aspergillosis in an immunocompetent patient.

## CASE PRESENTATION

A woman, age 34 years, unmarried, was admitted to the hospital with a complaint of a lump and pain in the abdomen

for the last two months associated with on and off fever with chills. The past medical history of the patient was insignificant. The patient denied having any recent infections, sexual activities or vaginal discharge and her last menstrual period was one month before.

The patient's BMI was 24.5, her vital signs were steady, and pallor was visible upon general examination. The breast and systemic examinations of the patient were also normal. The patient did not have diabetes, and her serological tests for HBsAg, HCV, and HIV were all negative. The findings of the laboratory tests, including the complete hemogram, liver function test, renal function test, and CA-125,  $\alpha$ -fetoprotein (AFP), carbohydrate antigen 19-9 (CA19-9), and carcinoma embryonic antigen (CEA) assay results were also within the normal range.

The abdomen of the patient appeared soft but tender and a mass measuring 10x8.5 cm was felt on the left side of the lower abdomen during a vaginal examination. The contrast enhanced tomography (CECT) of the whole abdomen showed a heterogeneous enhancing solid cystic lesion with septations measuring 10x9.5x9.0 cm in the left ovary (Figure 1A). As a result, a provisional diagnosis of left ovarian neoplasm was considered. Left-sided salpingo-oophorectomy was done.

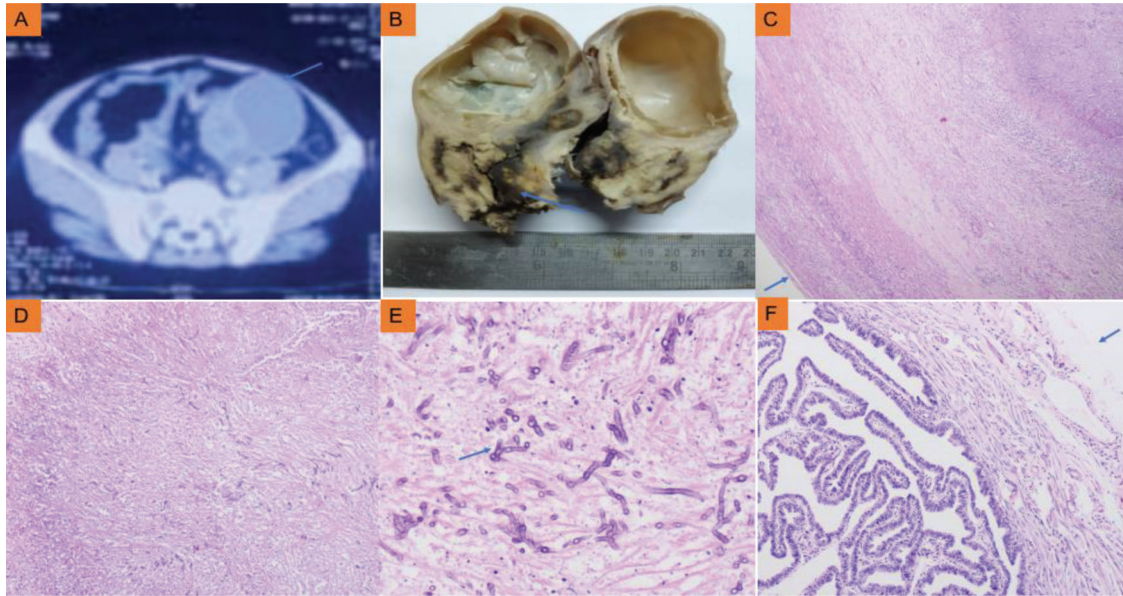
Gross findings of the left ovary specimen were showing a mass measuring 11 x 9.0 x 8.5 cm. The fallopian tube measured 4.5 cm in length. The outer surface of the ovary mass was encapsulated and light yellow serous fluid was seen oozing upon the incision. The cut surface of the incised mass showed cystic and solid areas with interspersed black pigmentation (Figure 1B).

The Hematoxylin and Eosin (HE) and Periodic acid Schiff (PAS) stained sections of the ovarian mass were showing dense inflammation, and necrosis. They were having florid

Received: February 2023; Accepted after review: March 2023;

Published: March 2023.





**Fig. 1.** A. CECT of the whole abdomen showed heterogeneously enhancing solid cystic left ovary mass with septations; B. Left ovary mass displaying solid-cystic areas with black pigmentation; C. The histological examination of the left ovary mass shows dense inflammation, necrosis and scattered numerous fungal hyphae covered by a thick capsule (HE, 40x); D. Necrotic debris with interspersed fungal elements (HE, 100x); E. Florid fungal septate hyphae displaying acute angle branching (PAS, 400x); F. Microscopy of left fallopian tube reveals unremarkable histology (HE, 100x).

fungal septate hyphae with dichotomous branching and was diagnosed as ovarian Aspergillosis (Figures 1C-E). The microscopy of sections from the left fallopian tube showed unremarkable histology (Figure 1F).

After a diagnosis of ovarian aspergillosis, the patient was given an intravenous formulation of voriconazole (6 mg/kg/day) and liposomal amphotericin B (0.5 mg/kg/day) for a period of ten days. In retrospect, a CECT of the thorax was suggested to rule out focus in the respiratory tract, which revealed no abnormality. The patient was then discharged and followed in the outpatient department after one and six months. Currently, the patient is in good condition.

## DISCUSSION

Aspergillus are widespread saprophytic fungi frequently found in soil and decomposing plant matter. These can cause infections in humans upon inhalation of airborne conidia. Aspergillosis causes a wide range of clinical disorders with diverse symptoms depending on the region of involvement and the host immunological response. Aspergillosis mostly affects the respiratory system and its associated structures [10].

Genitourinary tract infections are quite common in females of developing nations, due to unsanitary conditions. Chronic illnesses like diabetes mellitus are another contributing factor for such infections. Immunosuppressive therapies in patients with transplantation, graft rejection, neutropenia, intercurrent infections due to viruses, and other chronic illness are risk factors for invasive aspergillosis [11]. The patient under study was not immunocompromised and without any known drug history. Ovarian infections caused by fungi are quite rare. Fungi of *Candida* species are the usual culprits of ovarian fungal infections in most cases. Despite the fact that *Aspergillus* hyphae are typically described as acute branching septate hyphae, it is often difficult to identify and

distinguish them from hyphal forms of other fungi like *Pseudallescheria abode*, *Fusarium species*, and *Candida spp.* Identification and confirmation of *Aspergillus* often require microbiological isolation via culture. A histological diagnosis can be done once the fruiting bodies of the *Aspergillus* fungus have been observed [12]. Molecular methods like polymerase chain reaction can be used for the detection of *Aspergillus* DNA [13]. Whenever the presence of *Aspergillus* is confirmed in any clinical specimen, further investigations are needed to rule out a systemic focus. No systemic involvement was found in this case study on the CECT of the thorax.

Some species of *Aspergillus* are more resistant to antifungal medication and are linked to increased mortality and virulence. Therefore, the identification of *Aspergillus* species can be more helpful in diagnosis [14]. Treatment of Aspergillosis is difficult due to increasing antifungal resistance. Antifungal drugs like Voriconazole and Liposomal Amphotericin B, being of a less toxic nature are more effective due to their lesser side effects. Their use in the treatment of serious fungal infections is advocated with complete surgical excision [15].

## CONCLUSION

Ovarian aspergillosis is a fungal infection, which may occur in an immunocompetent host and masquerade as ovarian neoplasm. Ovarian aspergillosis must be considered in a differential diagnosis of ovarian neoplasms; however, it is an extremely infrequent condition.

## Informed consent

Written informed consent was obtained from the patient for publication of this case report and accompanying images. A copy of the written consent is available for review by the Editor-in-Chief of this journal.

**Founding**

Not founded.

**Conflict of interest**

None.

**■ REFERENCES**

1. Harmouchi H, Sani R, Issoufou I, et al. Pulmonary aspergilloma: from classification to management. *Asian Cardiovasc Thorac Ann.* 2020;28(1):33-38. PMID: 31799858. doi: 10.1177/0218492319895113.
2. Singh V. Fungal Rhinosinusitis: Unravelling the Disease Spectrum. *J Maxillofac Oral Surg.* 2019;18(2):164-179. PMID: 30996535; PMCID: PMC6441414. doi: 10.1007/s12663-018-01182-w.
3. Taccone FS, Van den Abeele AM, Bulpa P, et al. Epidemiology of invasive aspergillosis in critically ill patients: clinical presentation, underlying conditions, and outcomes. *Crit Care.* 2015;19(1):7. PMID: 25928694; PMCID: PMC4344741. doi: 10.1186/s13054-014-0722-7.
4. Bongomin F, Gago S, Oladele RO, et al. Global and Multi-National Prevalence of Fungal Diseases-Estimate Precision. *J Fungi (Basel).* 2017;3(4):57. PMID: 29371573; PMCID: PMC5753159. doi: 10.3390/jof3040057.
5. Kleinschmidt-DeMasters BK. Central nervous system aspergillosis: a 20-year retrospective series. *Hum Pathol.* 2002;33(1):116-124. PMID: 11823982. doi: 10.1053/hupa.2002.30186.
6. Ho CL, Deruytter MJ. CNS aspergillosis with mycotic aneurysm, cerebral granuloma and infarction. *Acta Neurochir (Wien).* 2004; 146(8):851-856. PMID: 15254808. doi: 10.1007/s00701-004-0292-6.
7. Cumbo-Nacheli G, de Sanctis J. A near fatal case of invasive aspergillosis. *Am J Case Rep.* 2012;13:169-172. PMID: 23569520; PMCID: PMC3615918. doi: 10.12659/AJCR.883320.
8. Kostelnik FV, Fremont HN. Mycotic tubo-ovarian abscess associated with the intrauterine device. *Am J Obstet Gynecol.* 1976;125(2):272-274. PMID: 1266911. doi: 10.1016/0002-9378(76)90612-8.
9. Kim SW, Nah MY, Yeum CH, et al. Pelvic aspergillosis with tubo-ovarian abscess in a renal transplant recipient. *J Infect.* 2001; 42(3):215-217. PMID: 11545558. doi: 10.1053/jinf.2001.0791.
10. Cadena J, Thompson GR 3<sup>rd</sup>, Patterson TF. Invasive Aspergillosis: Current Strategies for Diagnosis and Management. *Infect Dis Clin North Am.* 2016;30(1):125-142. PMID: 26897064. doi: 10.1016/j.idc.2015.10.015.
11. Gillemain R, Lavarde C, Amrein P, et al. Invasive aspergillosis after transplantation. *Transplant Proc.* 1995;27(1):1307-1309.
12. Anila KR, Somanathan T, Mathews A, et al. Fruiting bodies of *Aspergillus*: An unusual finding in histopathology. *Lung India.* 2013;30(4):357-359. PMID: 24339500; PMCID: PMC3841699. doi: 10.4103/0970-2113.120623.
13. Aquino VR, Nagel F, Andreolla HF, et al. The performance of real-time PCR, galactomannan, and fungal culture in the diagnosis of invasive aspergillosis in ventilated patients with chronic obstructive pulmonary disease (COPD). *Mycopathologia.* 2012;174(2):163-169. PMID: 22382738. doi: 10.1007/s11046-012-9531-1.
14. Henry T, Iwen PC, Hinrichs SH. Identification of *Aspergillus* species using internal transcribed spacer regions 1 and 2. *J Clin Microbiol.* 2000;38(4):1510-1515. PMID: 10747135; PMCID: PMC86477. doi: 10.1128/JCM.38.4.1510-1515.2000.
15. Peral-Cagigal B, Redondo-González LM, Verrier-Hernández A. Invasive maxillary sinus aspergillosis: A case report successfully treated with voriconazole and surgical debridement. *J Clin Exp Dent.* 2014;6(4):e448-451. PMID: 25593673; PMCID: PMC4282918. doi: 10.4317/jced.51571.