

# A case report of pyogenic sacroiliitis in a 9-month-old child

Sarah Thomas\*, Saira Haque, Trisha Radia

King's College Hospital NHS trust, London, UK.

\*Corresponding author: Sarah Thomas. King's College Hospital NHS trust, Denmark Hill, London SE5 9RS, United Kingdom. Email: sarah.thomas55@nhs.net

**How to cite this article:** Thomas S, Haque S, Radia T. A case report of pyogenic sacroiliitis in a 9-month-old child. Arch Clin Cases. 2022; 9(3):108-111. doi: 10.22551/2022.36.0903.10213

## ABSTRACT

A very rare condition, pyogenic sacroiliitis is responsible for 1-2% of all osteoarticular infections in children. Diagnosis is often delayed in the pediatric population due to non-specific signs and symptoms during presentation, difficulty in assessing the joint, more common differential diagnosis and low yield diagnostic findings in conventional radiography. A delayed diagnosis of this condition can lead to permanent joint damage. A 9-month-old presented to the emergency department with a history of fever, being unsettled and clingy along with refusal to weight bear over the past few days. On initial assessment, she was found to be tachycardic and afebrile with abnormal posture of her left leg held in external rotation at the hip joint. On examination, she refused to weight bear, presented with alternating tenderness of her left and right hip joints and spinal tenderness at the L5 position. Investigations done showed slightly raised inflammatory counts, normal hip and pelvic radiographs, normal hip ultrasound and blood culture growing staphylococcus aureus and Magnetic Resonance Imaging spine showing right sacroiliitis leading the diagnosis of pyogenic sacroiliitis. This case report highlights the importance of examination of the back and the importance of avoiding fixation error by history. Although rare, clinicians should consider the diagnosis of sacroiliitis in children who present with fever, being unsettled with decreased and painful movements around the pelvic region

**KEYWORDS:** pyogenic sacroiliitis; osteo-articular infection; FABER test; 99Tcm-MDP bone scan; transient synovitis; septic arthritis

## ■ BACKGROUND

A very rare condition, pyogenic sacroiliitis is responsible for 1-2% of all osteoarticular infections in children [1,2]. Diagnosis is often delayed due to non-specific signs and symptoms during presentation, difficulty in assessing the joint, more common differential diagnosis and low yield diagnostic findings in conventional radiography [3,4]. A delayed diagnosis of this condition can lead to permanent joint damage. The diagnosis is made with Magnetic Resonance Imaging (MRI) scan of the spine [5-7] and the causative agent is identified by blood culture with the most common organism in the pediatric population being *Staphylococcus aureus* [8]. In response to antibiotic treatment, symptoms and healing begin to regress within a short period of time [1].

This is a case report of a rare presentation of pyogenic sacroiliitis diagnosed and managed in an infant. It focuses on the difficulties in making this diagnosis in a child of the non-verbal age group, the importance of examining the back when children present with tenderness around the pelvic

region, usefulness of various imaging modalities and avoiding fixation error by history.

Informed written consent has been obtained from mother of the infant.


## ■ CASE PRESENTATION

A 9-month-old infant consulted the pediatric emergency department with a history of fever, being more unsettled and clingier than normal over the past few days. On initial assessment, she was found to be afebrile and unsettled with normal systemic and joint examination. Initial investigations demonstrated slightly raised inflammatory markers with a normal white cell count. (Hb – 115 g/L, WCC-  $15.47 \times 10^9/L$ , Plt –  $308 \times 10^9/L$ , C-Reactive Protein – 36mg/L). A diagnosis of viral illness was made and she was discharged home with adequate safety netting advice and daily reviews by the hospital at home team.

Two days later, she was referred back to the emergency department by the hospital at home community team as she was refusing to weight bear and started crying every time someone tried to make her stand or bounce her. Prior to this, she used to stand/bounce with assistance and 'side step' with support.

**Received:** July 2022; **Accepted after review:** September 2022;

**Published:** September 2022.



On assessment, she was found to be tachycardic along with features of poor perfusion and on examination, her left leg was found to be held in abduction and external rotation at the hip joint and she was observed to be distressed during the examination of her pelvic region. Initial blood investigations done showed raised inflammatory markers with neutrophilic leukocytosis (WCC –  $29.42 \times 10^9/L$ , Hb – 102 g/L, Plt –  $563 \times 10^9/L$ , CRP – 58 mg/L, ESR – 40mm/1h). A pelvic and hip radiograph was performed which demonstrated normal bone density, no fracture and no destructive bony pathology. She was adequately resuscitated and stabilized in the emergency department and started on management for septic arthritis with antibiotics which consisted of intravenous ceftriaxone. This was done in view of the raised inflammatory counts (ESR & CRP) and clinical presentation.

Once on the ward, she was reviewed by multiple teams which included the orthopedic team, general pediatric team, physiotherapists who found her to have non-specific features such as alternating pain of her right and left hip joints on movement with each day and advice was sought from radiologists and microbiologists for her management.

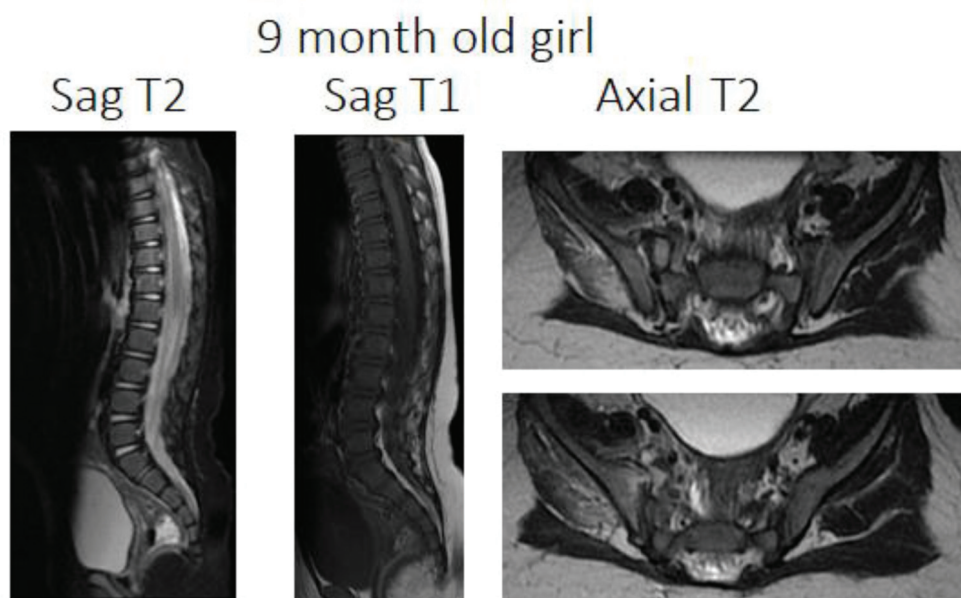
As she continued to be unwell with no clear focus and raised inflammatory counts, we suspected septic/arthritis/osteomyelitis and were looking for the best imaging modality. Subsequent imaging of her joints included an ultrasound of both hip and knee joints was normal. There was no joint effusion and no abnormal synovial thickening. No abnormal vascularity was demonstrated. The soft tissues anterior to the femora were normal with no subperiosteal collection. An abdominal ultrasound scan performed at the same time was normal with no focal masses no hepatosplenomegaly and no intra-abdominal or pelvic source of infection identified. As part of her work up, further investigations such as, an autoimmune work up, ECG, urine dipstick and

urine MC&S which were all performed and returned as normal. It was clear with her inflammatory marker rise and fever, there was a possible bacterial infection somewhere.

A new team took over the care over the weekend and besides examining her joints and limbs also proceeded to examine her back which revealed her to be tender over the spinal process at the L5 level with normal passive examination of her hips. This team proceeded to undertake further imaging with an MRI scan of her spine and pelvis under general anesthesia which showed the scan of the spine to be normal. However, the scan of the pelvis demonstrated the abnormal right sacro-iliac joint, periarticular marrow oedema, thickening of the joint capsule with extracapsular oedema tracking anteriorly along the posterior margin of the iliopsoas muscle. The edema also tracked posteriorly into the right gluteal muscles. No drainable collection was identified following contrast administration. (Figure 1).

During that same time, her blood culture was reported to be growing staphylococcus aureus and these findings led to a diagnosis of the rare condition of acute pyogenic sacroiliitis.

After discussion with the microbiologists, she was started on treatment for this condition which consisted of flucloxacillin for a total of 6 weeks (two weeks intravenous and four weeks oral) along with appropriate physiotherapy to which she responded very well. A repeat set of blood investigations done a week later showed a lowering of her inflammatory markers (WCC –  $12.31 \times 10^9/L$ , Hb – 141 g/L, Plt –  $488 \times 10^9/L$ , CRP <1 mg/L, ESR – 5 mm/1h). She was also followed up in outpatient clinic a few weeks later and showed a rapid progress in her recovery. She did not have any further temperature spikes and started weight bearing once again with no pain or tenderness around her pelvic region.



**Fig. 1.** Sagittal T1 and T2-weighted sequence of the lower thoracic and lumbo-sacral spine demonstrate normal bone marrow signal and normal intervertebral disc spaces. Axial T2-weighted sequences of the pelvis demonstrate thickened, edematous anterior joint capsule of the right sacro-iliac joint with anterior extracapsular oedema tracking along the posterior margin of the iliopsoas muscle. Further oedema extends posteriorly towards the right gluteus minimus and medius muscles. Peri-articular marrow edema is seen on the iliac side of the right sacroiliac joint and no erosions demonstrated.

## DISCUSSION

An extensive literature review was conducted by Schaad et al regarding 77 children with pyogenic sacroiliitis from 1941 to 1979 [3]. In a series of 33 cases of pyogenic sacroiliitis, Wu et al. identified 11 cases younger than 15 years old [4]. Eight patients with sacroiliitis that were identified between 2000 and 2005 were reviewed by Wada et al [9]. According to Molinos Quintana et al., 11 patients under the age of 14 years were diagnosed with pyogenic sacroiliitis during the eight years 2002-2010 [10]. From a literature review of 20 cases of sacroiliitis in preschool children, Alcobendas et al. found that refusal to sit was the most presentation of this condition [11].

Pyogenic sacroiliitis is a very rare under-recognized osteo-articular infection in the pediatric age group which usually affects children of the older age group [1,2]. It is quite exceptional to occur at a young age such as 9 months [12].

The diagnosis to this condition was slightly delayed in our child due to clinical and epidemiological characteristics that complicates the diagnosis such as being afebrile during presentations, initial response to analgesia and the slow rise in her inflammatory markers [1,9,13,14]. A clinical examination of the back is particularly difficult, especially if the child is not yet able to speak [1,15]. The Patrick or FABER test (Flexion, ABduction, External Rotation) which can usually be used for determining pain at the sacroiliac region could not be used in this case due to the age our patient which also indicates the difficulty in diagnosis of this condition in younger age groups [2].

Moreover, decreased weight bearing at this age is usually caused by other more common conditions such as transient synovitis and septic arthritis [5] for which this child was investigated as well.

This condition was diagnosed with an MRI scan of her spine and pelvis. MRI is the imaging technique with the highest sensitivity (100%) and specificity (100%) for the diagnosis of pyogenic osteomyelitis [6-8]. It detected the degree of oedema and inflammation indicative of infection and also helped plan management because of the absence of local abscess formation and spinal involvement which is important in the decision of surgical intervention [16,17].

The other modes that have been previously discussed for the diagnosis of this condition are Plain Xray and Ultrasound that can be used to exclude effusions at the joints. There is a high degree of sensitivity to 99Tcm-MDP bone scans for bone and joint sepsis, but they lack specificity due to the fact that other conditions may cause increased uptake in the sacroiliac joints similar to other nuclear medicine scans which lack the sensitivity of an MRI scan for this condition [2,19].

*Staphylococcus aureus* which was isolated from the child's blood culture was the main causative organism for this condition [8].

It has also been reported that children have developed sacroiliitis caused by *Staphylococcus epidermidis*, *Streptococcus* (Group A, B), *Citrobacter freundii*, *Salmonellas*, *Bacillus subtilis*, and *Escherichia coli* [1,18].

While symptoms rapidly disappear with appropriate antibiotic therapy and management, very few patients require surgical intervention despite their young age and delayed start of treatment [1,15].

## CONCLUSION

This case report highlights the importance of examination of the back and the importance of avoiding fixation error by history. Although rare, clinicians should consider the diagnosis of sacroiliitis in children who present with fever, being unsettled with decreased and painful movements around the pelvic region after ruling out more common conditions such as septic arthritis of hip joints and transient synovitis.

### Consent for publication

Written consent obtained from mother of child.

### Availability of data and materials

The data that support the findings of this study are available from authors, but restrictions apply to the availability of these data and are not publicly available. Data are however available from the authors upon reasonable request and with permission of patient's guardian/parent.

### Competing interests

The authors declare that they have no competing interests.

### Funding

No funding body.

## REFERENCES

- Leroux J, Bernardini I, Grynberg L, et al. Pyogenic Sacroiliitis in a 13-Month-Old Child: A Case Report and Literature Review. *Medicine (Baltimore)*. 2015; 94(42):e1581. doi: 10.1097/MD.0000000000001581. Erratum in: *Medicine (Baltimore)*. 2015; 94(52):e8190.
- Ford LS, Ellis AM, Allen HW, et al. Osteomyelitis and pyogenic sacroiliitis: a difficult diagnosis. *J Paediatr Child Health*. 2004; 40:317-319. doi: 10.1111/j.1440-1754.2004.00372.x.
- Schaad UB, McCracken GH, Nelson JD. Pyogenic arthritis of the sacroiliac joint in pediatric patients. *Pediatrics*. 1980; 66:375-379. doi: 10.1542/peds.66.3.375.
- Wu M-S, Chang S-S, Lee S-H, et al. Pyogenic sacroiliitis: a comparison between paediatric and adult patients. *Rheumatol Oxf Engl*. 2007; 46:1684-1687. doi: 10.1093/rheumatology/kem201.
- McPhee E, Eskander JP, Eskander MS, et al. Imaging in pelvic osteomyelitis: support for early magnetic resonance imaging. *J Pediatr Orthop*. 2007; 27:903-909. doi: 10.1097/bpo.0b013e31815a6616.
- Bigot J, Loeuille D, Chary-Valckenaere R et al. Determination of the best diagnostic criteria of sacroiliitis with MRI. *J Radiol*. 1999; 80: 1649-1657.
- Haliloglu M, Kleiman MB, Siddiqui AR, et al. Osteomyelitis and pyogenic infection of the sacroiliac joint. MRI findings and review. *Pediatr Radiol*. 1994; 24:333-335. doi: 10.1007/BF02012119.
- Taylor ZW, Ryan DD, Ross LA. Increased incidence of sacroiliac joint infection at a children's hospital. *J Pediatr Orthop*. 2010; 30:893-898. doi: 10.1097/BPO.0b013e3181f8bebe5.
- Wada A, Takamura K, Fujii T, et al. Septic sacroiliitis in children. *J Pediatr Orthop*. 2008; 28:488-492. doi: 10.1097/BPO.0b013e31816d7214.
- Molinos Quintana A, Morillo Gutiérrez B, Camacho Lovillo MS, Neth O, Obando Santaella I. Pyogenic sacroiliitis in children- a diagnostic challenge. *Clin Rheumatol*. 2011; 30(1):107-113. PMID: 20706753. doi: 10.1007/s10067-010-1549-5.
- Alcobendas RM, Loza SM, Camba AR, Gascon CU, Rey CC. Sacroiliitis in Preschool Children: A Case Series and Review of the Literature. *Pediatr Infect Dis J*. 2020; 39(9):e272-e274. PMID: 32427647. doi: 10.1097/INF.0000000000002691.
- Chiu CH, Lin TY, Hung PC, et al. Pyogenic sacroiliitis in children: report of three cases. *Zhonghua Minguo Xiao Er Ke Yi Xue Hui Za Zhi J Zhonghua Minguo Xiao Er Ke Yi Xue Hui*. 1992; 33:313-321.
- Abbott GT, Carty H. Pyogenic sacroiliitis, the missed diagnosis? *Br J Radiol*. 1993; 66:120-122. doi: 10.1259/0007-1285-66-782-120.

14. Shanahan MD, Ackroyd CE. Pyogenic infection of the sacro-iliac joint. A report of 11 cases. *J Bone Joint Surg Br.* 1985; 67:605-608. doi: 10.1302/0301-620X.67B4.4030859.
15. Komatsu H, Nojiri H, Sogo T, et al. Sacroiliitis infected with group A streptococcus in a child presenting with confusion and combative-ness. *J Infect Chemother Off J Jpn Soc Chemother.* 2009; 15:328-330. doi: 10.1007/s10156-009-0709-5.
16. Aprin H, Turen C. Pyogenic sacroiliitis in children. *Clin Orthop.* 1993:98-106.
17. Doita M, Yoshiya S, Nabeshima Y, et al. Acute pyogenic sacroiliitis without predisposing conditions. *Spine.* 2003; 28:E384-E389. doi: 10.1097/01.BRS.0000092481.42709.6F.
18. Perez A, Padilla E, Marco A, et al. Pneumococcal sacroiliitis in a 4- year-old boy. *Scand J Rheumatol.* 2008; 37:310-312. doi: 10.1080/03009740801908019.
19. Sueoka BL, Johnson JF, Enzenauer R, et al. Infantile infectious sacroiliitis. *Pediatr Radiol.* 1985; 15:403-415. doi: 10.1007/BF02388361.