

## Epstein Barr virus infection and acalculous cholecystitis, a rare association in a pediatric patient

Laura-Mihaela Trandafir<sup>1,2</sup>, Doina Mihailă<sup>3</sup>, Mădălina Ionela Chiriac<sup>\*,4</sup>, Ioan Sârbu<sup>1,5</sup>, Carmen Iulia Ciongradi<sup>1,5</sup>

<sup>1</sup>"Grigore T. Popa" University of Medicine and Pharmacy, Iași, Romania, <sup>2</sup>III<sup>rd</sup> Pediatric Department, "Sf. Maria" Clinical Emergency Hospital for Children, Iasi, Romania, <sup>3</sup>Pathology Department, "Sf. Maria" Clinical Emergency Hospital for Children, Iasi, Romania, <sup>4</sup>Endocrinology Department, Clinical County Emergency Hospital Cluj-Napoca, Cluj-Napoca, Romania, <sup>5</sup>Pediatric Surgery Department, "Sf. Maria" Clinical Emergency Hospital for Children, Iasi, Romania

### Abstract

Acute acalculous cholecystitis associated with Epstein Barr virus (EBV) infection is a known entity, as opposed to the extremely rare cases of cystic duct stenosis secondary to EBV-related inflammation. The authors present the case of a 10-year-old male patient admitted with altered general state, anorexia, painful and distended abdomen. The patient had a history of EBV acute hepatitis two years prior to the current presentation, diagnosed based on clinical examination (fever, vomiting, and severe pain of right upper abdominal quadrant), and abdominal ultrasound revealing acute acalculous cholecystitis with gallbladder hydrops; still no indication for surgical treatment was made. The clinical outcome was favorable, but during those two years he suffered two episodes of chronic acalculous cholecystitis exacerbation, which required a MRI examination, indicating gallbladder hydrops and narrowing of terminal segment of the cystic duct (secondary inflammatory processes). The biological investigations revealed cholestasis, hepatocytolysis and inflammatory syndrome and the abdominal-ultrasound indicates an acalculous gallbladder and gallbladder hydrops. After cholecystectomy, the histopathological examination revealed chronic inflammation of the gallbladder wall, setting the diagnosis of exacerbation of chronic acalculous cholecystitis. Particularly for the case is the development of cystic duct stenosis, after the EBV acute infection. The clinical and laboratory outcome (monitored after 1, 3, 6, and 12 months) was favorable.

**Keywords:** *acalculous cholecystitis, Epstein - Barr virus, infection, gallbladder, hydrops, child, cholecystectomy*

### Introduction

Acute acalculous cholecystitis includes 5% to 10% of all adults with acute cholecystitis but is rarely diagnosed among pediatric patients [1-3]. The association of acute cholecystitis during viral infections especially in primary infection with Epstein Barr virus (EBV) and

cytomegalovirus (CMV) occurs rarely, usually at immune-suppressed patients, while the immune-competent patients are asymptomatic. Moreover EBV can cause hepatitis, cholestasis or pancreatitis [4, 5].

### Case report

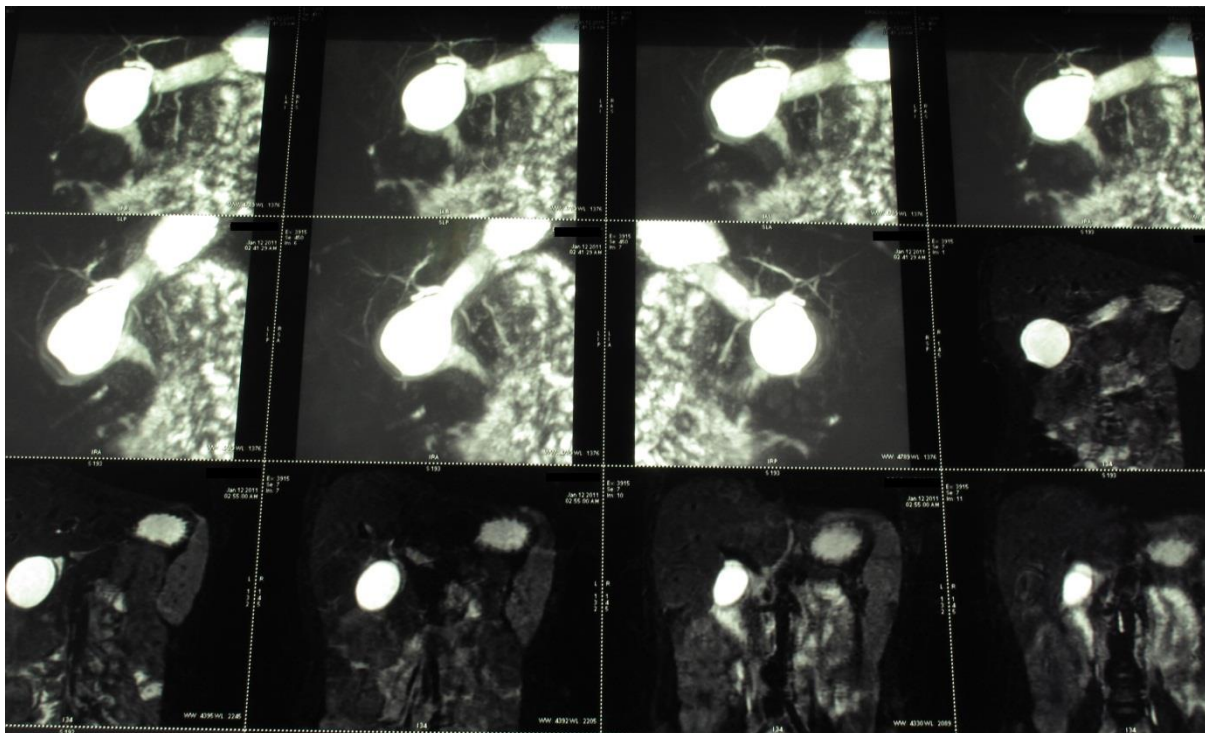
The authors present the case of a 10 year old male child previously hospitalized in III<sup>rd</sup> Pediatric Clinic of "Sf. Maria" Clinical Emergency Hospital for Children, Iasi, Romania, in January 2011, accusing nausea, vomiting, cough, stomach ache, pain in the

Received: October 2015; Accepted after review: December 2015; Published: December 2015.

\*Corresponding author: Mădălina Ionela Chiriac MD, Endocrinology Department, Clinical County Emergency Hospital Cluj-Napoca, 3 - 5 Pasteur Street, Cluj-Napoca, Romania.  
Email: [madalina.ionelachiriac@yahoo.com](mailto:madalina.ionelachiriac@yahoo.com)

right upper abdominal quadrant. The biological investigations revealed inflammatory syndrome, hepatocytolysis syndrome (ALT = 168 U/L, AST = 163 U/L), anti - Epstein Barr virus antibodies positive (EBV type Ig M antibody = 65.5 u/ml, type Ig G antibody = 36.29 u/ml), CMV type IgG antibodies = 36.29 u/ml, Helicobacter pylori type Ig G antibodies positive (13.2 U/ml), negative HBs Antigen and *Toxoplasma gondii* antibodies. The abdominal ultrasound initially described normal sized liver, normal reflectivity and homogeneous structure, slightly distended gallbladder without stones, and increased long axis spleen size (122 mm against the normal value <110 mm). The history of the patient revealed that symptoms (altered general condition, vomiting, and intense abdominal pain in medium, right and left upper abdominal quadrant) appeared after unfollowed liver diet and a high fat meal. The abdominal X- ray was normal. Biological

investigations revealed reactive pancreatitis sustained by high level of serum amylase (62 U/L), urine amylase (536 U/L), alkaline phosphatase (414 U/L) and erythrocyte sedimentation rate - ESR (15 mm/h). After 3 days of admission another abdominal ultrasound was performed revealing acalculous gallbladder and gallbladder hydrops, with volume of 60 ml. Subsequently, an abdominal computer tomography (abdomen-CT) was performed which confirmed the gallbladder hydrops and acalculous gallbladder. Consequently, an abdominal MRI was performed, highlighting acalculous gallbladder, gallbladder hydrops and stenosis in the terminal segment of cystic duct with suspicion of cystic duct fibrosis or atresia at this level, possible squealer of inflammatory phenomena with normal common bile duct and intrahepatic biliary ducts (Figure 1).



**Fig. 1.** Abdominal MRI - seriate sections of cystic duct stenosis and gallbladder without gallstones

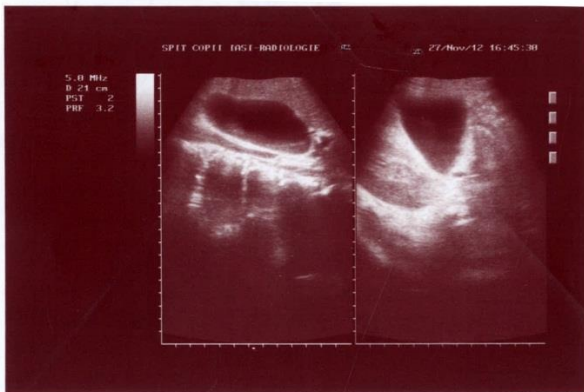
Therefore surgical consult was performed but considering the age and clinical outcome of the patient, we decided conservative treatment of the acute episode. Under diet and medical treatment for acute hepatitis and gallbladder hydrops (Ampicillin, Arginine, Ursodeoxycholic acid and Drotaverine) the

clinical outcome during hospitalization was slowly favorable. The clinical and biological investigation after 14 days (normal liver enzymes, AST = 23 U / L, ALT= 30U/L and pancreatic enzyme - amylase), 3 and 6 months objectified improving general condition and laboratory data. After 2 months the

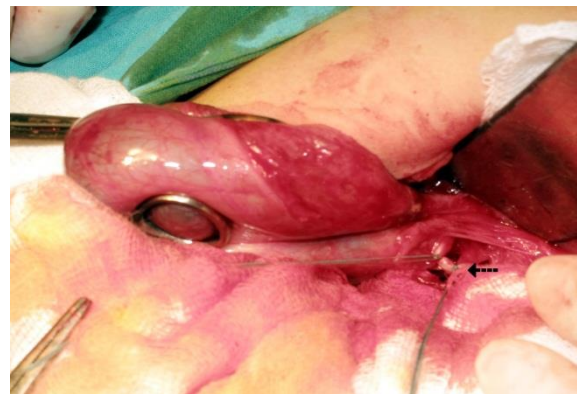appearance of gallbladder hydrops decreased with partial remission (a volume of 60 ml to each of 20 ml). Subsequently between 2 and 18 months from the first admission, the child suffered two episodes of hepatocytolysis syndrome (mild increase of transaminases, AST = 43 U/L and ALT = 86 U/L) and gallbladder hydrops gradually increased (from a volume of 20 ml to 72 ml). The clinical outcome was favorable but the gallbladder

hydrops was present (Figure 2) until November 2012, when the surgery was performed.

The surgery was performed under general anesthesia, with median laparotomy approach, cholecystectomy (Figure 3) and drainage of the subhepatic area. In order to achieve hemostasis and protect the remaining liver gallbladder bed an absorbable fibrin sealant patch was placed at this level.



**Fig. 2.** Abdominal ultrasound revealed gallbladder hydrops and gallbladder without gallstones



**Fig. 3.** Intra-operative appearance of the gallbladder, cystic duct ligature (mark highlights)

The clinical outcome after surgery was favorable, with drainage tube removed after 72 hours and the patient was discharged 6 days after surgery.

Histopathological examination of the specimen revealed exacerbation of chronic cholecystitis, gallbladder wall with mucosal folds, some of them entering the blanket muscle (Rokitansky sinuses) and chronic inflammation.

The child was subsequently follow-up for 18 months, maintaining specific diet and being completely asymptomatic during this period.

## Discussions

Cholecystitis or inflammation of the gallbladder is most commonly secondary to gallstones obstruction of the bile duct leading to distension of the gallbladder. It can also occur in the absence of gallstones, the first case described in literature at child being reported in 1966. Acute acalculous cholecystitis is assigned a higher mortality rate

because associated with sepsis, burns, trauma, total parenteral nutrition, severe dehydration and several infections [6, 7].

The primary EBV infection, also known as infectious mononucleosis is usually asymptomatic or clinically manifests in adolescents and young adults with fever, pharyngitis, adenopathy, splenomegaly in 24.7% and hepatomegaly in 12.3% of cases and hepatocellular dysfunction [8].

Acute acalculous cholecystitis associated with infectious mononucleosis is rarely described in the literature. The incriminated pathogenic mechanisms include biliary stasis and viral invasion of the gallbladder, although the pathogenesis of acute acalculous cholecystitis remains uncertain. Recent experimental data show that EBV infects CD8 + T cells that accumulate in the liver and produce IFN- $\gamma$ , TNF- $\alpha$  and Fas type ligand that can kill the hepatocytes [7-9]. In the acute primary EBV infection, the liver involvement is common. Mild to moderate increases of liver enzymes were observed in 80% to 90% of patients, while jaundice may appear only in

5% of cases. Hepatic impairment has rarely been reported. According to a study in adult patients, hepatitis caused by primary EBV infection was considered benign and resolved spontaneously within 5 weeks. However, there are few data on the clinical features and natural course of primary EBV hepatitis in children [8]. Involvement of pancreas (increased levels of amylase enzyme) associated with primary EBV hepatitis has also been reported in the literature. The mechanism remains unknown, being incriminated multifactorial causes, a pathogenesis hypothesis can be explain by a possible destruction of pancreatic acinar cells caused by virus [4].

The first cases of pediatric gallbladder hydrops, also known as acute distension of the gallbladder without stones or inflammation, have been reported since 1933 [10].

The differential diagnosis includes acute lithiasic cholecystitis and congenital malformations, of which the most common are congenital cyst of the cystic duct and congenital cystic duct stenosis [11 - 14].

In our case, congenital malformations were infirmed by the case history, the intra-operative appearance of cystic duct and the abdominal MRI examination. Cystic fibrosis was also considered [6] but the "sweat test" value was normal. The diagnosis in our case was sustained by the case history (there wasn't detected any evidence to suggest malformations), laboratory (primary EBV infection with high titers of type Ig-M antibodies) and imagistic investigations. Moreover in our case, regarding the clinical context, it was an atypical primarily EBV infection, as the peak incidence of mononucleosis infection occurs in adolescents and young adults [15, 16], the clinical manifestations was not typical for mononucleosis infection.

We mention that the patient was immune-competent, without autoimmune deficits, viral diseases, malignancies to induce immune-suppression status.

Because in most cases of acute acalculous cholecystitis the surgery is postponed [15] and the size of gallbladder was initially decreasing (from a volume of 60 ml to 20 ml) the surgical consult decided to delay

the surgery, mentioned that the child has no indication for emergency surgical treatment. When the exacerbations repeated with progressive increase size of the gallbladder (74/ 38 mm to 80/48 mm) associated with risk of perforation it was decided to proceed the surgery. Clinical and biological monitoring postoperatively at 1, 3, 6 and 12 months was favorable without symptomatic complaints.

Acute acalculous cholecystitis comprises 5% to 10% of all adult patients with acute cholecystitis and is rarely diagnosed in pediatric patients, acute acalculous cholecystitis and mononucleosis infection associated with vesicular hydrops is uncommon disease in pediatric pathology, there are only 13 cases reports published between 1994 and 2014 [15, 16].

In the case reported we consider gallbladder inflammation associated with primary EBV infection. The peculiarity of the case is the fact that after infectious mononucleosis associated with acute hepatitis and acute acalculous cholecystitis the child has secondary developed a symptomatic cystic duct stenosis, making the surgical treatment mandatory two years later. Usually, symptomatic treatment is enough in cases of acute cholecystitis caused by EBV. The cholecystectomy is rarely practiced in cases of acute acalculous cholecystitis [16], only one case was reported in the literature.

In our case the cholecystectomy was performed due to repeated exacerbations of acute cholecystitis, possibly in context of cystic duct stenosis, diagnosed by abdominal IRM.

## Conclusion

Acute acalculous cholecystitis occurs rarely of all adult patients with acute cholecystitis but among the pediatric patients this pathology is rare. In this case we consider that acute acalculous cholecystitis and gallbladder hydrops are inflammatory complication, secondary to the primary EBV infection, considering that the initial abdominal ultrasound showed a normal gallbladder. The peculiarity of the case is the fact that after infectious mononucleosis associated with acute hepatitis the child has developed a

symptomatic cystic duct stenosis, leading to vesicular hydrops and the necessity of surgical

treatment. The clinical outcome after surgery was favorable.

## References

1. Gora-Gebka M, Liberek A, Bako W, Szarszewski A, Kamińska B, Korzon M. Acute acalculous cholecystitis of viral etiology-a rare condition in children? *J Ped Surg* 2008; 43:E25-E27.
2. Iaria C, Arena L, Di Maio G, et al. Acute acalculous cholecystitis during the course of primary Epstein-Barr virus infection: a new case and a review of the literature. *Int J Inf Dis* 2008; 12:391-395.
3. Attilakos A, Prassouli A, Hadjigeorgiou G, et al. Acute acalculous cholecystitis in children with Epstein-Barr virus infection: a role for Gilbert's syndrome? *Int J Inf Dis* 2009; 13:e161-e164.
4. Kang S-J, Yoon K-H, Hwang J-B. Epstein-Barr virus infection with acute pancreatitis associated with cholestatic hepatitis. *Pediatr Gastroenterol Hepatol Nutr* 2013; 16(1):61-64.
5. Park JH, Noh JC, Park HM, et al. A case of Epstein-Barr virus infection with gall bladder and common bile duct stones in an otherwise healthy child. *Pediatr Gastroenterol Hepatol Nutr* 2012; 15(1):57-61.
6. Shreders A, Michie C. Acalculous cholecystitis in 14-year old boy with no predisposing factors. *The West London Medical Journal* 2010; 12(2):11- 14.
7. Prassoulia A, Panagiotou J, Vakakib M et al. Acute acalculous cholecystitis as the initial presentation of primary Epstein-Barr virus infection. *J Ped Surg* 2007; 42:E11-E13.
8. Yang SI, Geong JH, Kim JY. Clinical characteristics of primary Epstein Barr virus hepatitis with elevation of alkaline phosphatase and  $\gamma$ -glutamyltransferase in children. *Yonsei Med J* 2014; 55(1):107-112.
9. Nagdev A, Ward J. Bedside Ultrasound diagnosis of acalculous cholecystitis from Epstein-Barr virus. *West J Emerg Med* 2011; 12(4):481-483.
10. Rumley TO, Rodgers BM. Hydrops of the gallbladder in children. *J Ped Surg* 1983; 18(2):138-40.
11. Shaffer EA. Gallbladder disease. In: Walker WA, Durie PR, Amilton JR, et al. *Pediatric Gastrointestinal Disease*. 3-rd ed. B.C. Decker Inc 2000. Chapter 65. Pg: 1291-1311.
12. Schwarz SM, Hebra A. Pediatric Cholecystitis. 2015. [<http://emedicine.medscape.com/article/927340-overview> available at 12/28/2015]
13. Jeo CJ. Shackelford's Surgery of the alimentary tract. Vol II. Sixth edition. Philadelphia: Saunders Elsevier, 2007.
14. Parisi GF, Di Dio G, Franzonello C, et al. Liver disease in cystic fibrosis: An Update. *Hepat Mon* 2013; 13(8):e11215.
15. Poddighe D, Cagnoli G, Masticci N, Bruni P. Acute acalculous cholecystitis associated with severe EBV hepatitis in an immunocompetent child. *BMJ Case Rep* 2014.
16. Hamdy RF, Stein RE, Larru B, et al. Gallbladder wall thickening in an adolescent with acute mononucleosis: A case report and brief review of the literature. *JPIDS* 2014; 1-5.