

## Case report

# Non-Vitamin K oral anticoagulant treatment – behind the mask there is a story

Mădălina-Ștefana Mihai<sup>\*,1</sup>, Anca Ouatu<sup>2,3</sup>, Anca Trifan<sup>1,3</sup>, Cătălin Sfarti<sup>1,3</sup>

<sup>1</sup>Gastroenterology and Hepatology Clinic, "Sf. Spiridon" Clinical Emergency Hospital, Iași, Romania; <sup>2</sup>III<sup>rd</sup> Medical Clinic, "Sf. Spiridon" Clinical Emergency Hospital, Iași, Romania; <sup>3</sup>"Grigore T. Popa" University of Medicine and Pharmacy, Iași, Romania

## Abstract

Pelvic radiation disease is a term related to complications developed after radiotherapy used for pelvic cancers. Symptomatology can be overt, dull or even absent depending on variable factors. We present the case of a 78-year-old female patient with a declared post-partum hysterectomy, known cardiovascular disease, and fatigue and dizziness as main symptoms. She was diagnosed with pelvic radiation disease only after the symptoms were triggered by a non-vitamin K anticoagulant treatment and carefully reassessed anamnesis. Despite it being a predictable condition in patients receiving pelvic radiation, the disease is underdiagnosed, clinicians often overlooking the scale of the problem by treating the symptoms or by focusing on a small fraction of the disease within their medical branch. The case presented displays the value of shifted focus from survivorship to life quality and the importance of patient-tailored management. Sometimes, complementary therapy uncovers a masked illness which can initially be a real challenge but early diagnosis can lead to a satisfactory medical outcome.

**Keywords:** *pelvic radiation disease; non-vitamin K oral anticoagulants; atrial fibrillation*

## Introduction

Radiotherapy (RT) used to treat low gastrointestinal (GI) and urogenital neoplasms also involves acute and chronic complications acknowledged as pelvic radiation disease (PRD), with various clinical forms depending on anatomical localization, radiation type and dosage, age at exposure, ethnicity, and genetic factors [1].

Ionizing radiation's maximal effect is seen in high turnover tissues like bone marrow, gastrointestinal and skin epithelium [2]. This turns it to a great treatment modality for rapidly proliferating tumor cells but also explains

the vulnerability of these tissues, their damage becoming a predictable status. According to their time of onset, there are three stages of PRD: acute, chronic and latent [1]. In the acute phase clinical manifestations are limited, but in the chronic and latent stage symptomatology varies widely between slightly discomfort and life threatening disability, the quality of life being decreased [3].

Atrial fibrillation (AF) is one of the major causes of stroke, heart failure, sudden death, and cardiovascular morbidity [4]. Its management includes oral anticoagulants like vitamin K antagonists (VKA) or non-vitamin K oral anticoagulants (NOAC) and large studies demonstrated that NOACs are equal to VKAs in stroke prevention have a lower risk of intracranial hemorrhage and a lower overall bleeding risk, but a higher incidence of gastrointestinal bleeding [5].

Received: October 2018; Accepted after review: December 2018; Published: December 2018.

\*Corresponding author: Mădălina-Ștefana Mihai, Gastroenterology and Hepatology Clinic, "Sf. Spiridon" Clinical Emergency Hospital, 1 Independenței Blvd, Iași, Romania  
Email: [madallina\\_mihai@yahoo.com](mailto:madallina_mihai@yahoo.com)



In a patient that survives a radio-treated pelvic cancer, the interference of anticoagulant therapy, a mandatory gesture in AF, can turn into a real challenge.

### Case report

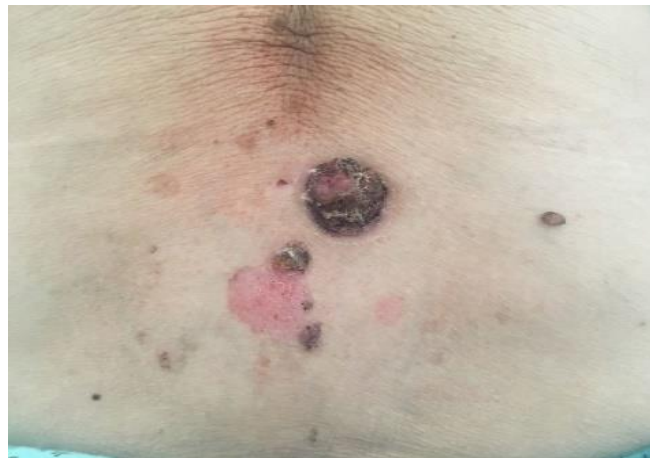A 78-year-old Caucasian female patient was admitted in the internal medicine department for non-specific symptomatology consisting in fatigue and dizziness that began a week earlier.

Her medical history revealed autoimmune thyroiditis, arterial hypertension stage three, and osteoporosis. Complications arose due to

a post-partum hysterectomy at an early age, which meant undergoing a complex and specific treatment. From the age of 74 the patients often develop AF and ventricular extrasystoles (VES). She also reported very frequent cystitis in the last five years.

Physical examination on admission showed tachycardia and arrhythmia, blood pressure: 160/100 mmHg, a lumbar ulcerated pigmented tumor of 3/2.5 cm diameter, another four similar surrounding lesions (Figure 1), abdominal scarring due to the post-hysterectomy, delayed gut transit, and pollakiuria.

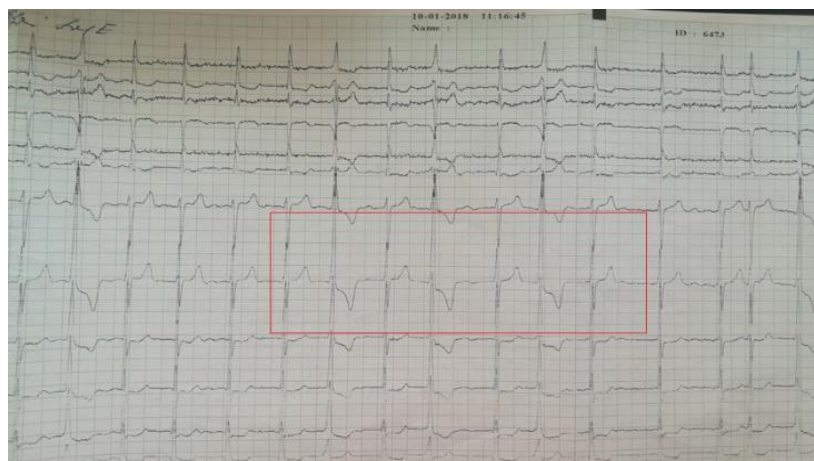
Biochemical analyses were in normal range. Urine culture was positive for *E. coli*.



**Fig. 1.** Lumbar ulcerated pigmented tumor

Dynamic electrocardiogram showed AF with high ventricular rate, left ventricular hypertrophy, ventricular bigeminy (Figure 2) and doublets. Holter electrocardiogram reveals

AF and over 10.000 VES/24h with numerous asymptomatic episodes of bigeminy, doublets, triplets and two episodes of asymptomatic non-sustained ventricular tachycardia.



**Fig. 2.** Electrocardiogram with ventricular bigeminy

A dermatological exam is needed for differential diagnosis between lumbar malignant melanoma, basal cell carcinoma, and cutaneous metastasis required for supplementary investigations.

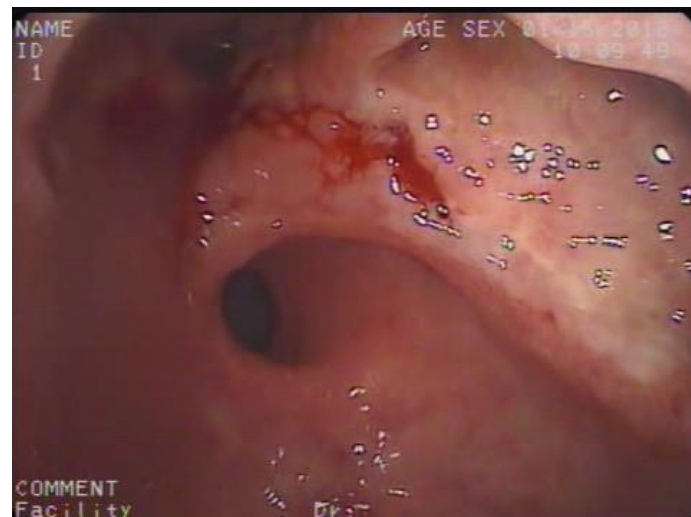
After the adjustment of antihypertensive therapy, initiation of antibiotics for cystitis and parenteral anticoagulant in the context of AF, the progress was favorable and the patient was discharged on treatment including NOAC (Dabigatran 150 mg twice daily).

Two months later the patient arrived at the emergency room with ongoing low GI bleeding and rectal tenesmus. A surgical exam revealed a circumferential tumor with irregular edges at 6-7 cm from the anal verge. A clinical exam also showed bleeding from the lumbar

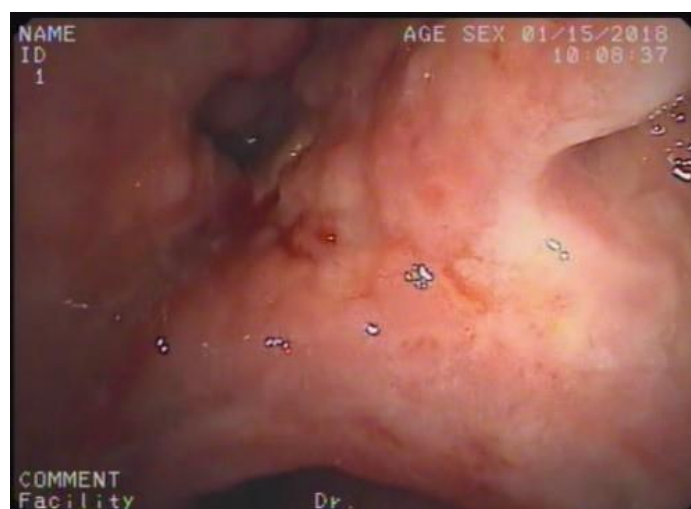tumor but the patient was hemodynamic stable.

Laboratory exams showed a mild drop in hemoglobin levels (11.2g/dl) and modified coagulogram in the context of Dabigatran treatment. Investigations (electrocardiogram, echocardiography, biochemical exams) confirmed stationary cardiovascular disease but a gastroenterological exam pointed to the high probability of a rectal neoplasm.

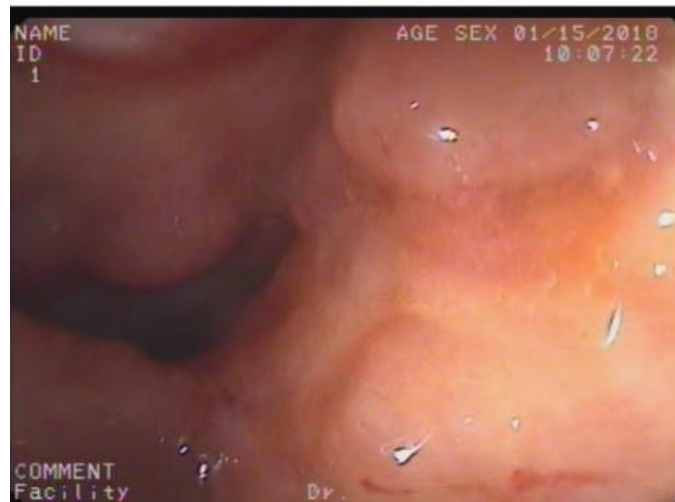A colonoscopy revealed a nearly circumferential infiltrative ulcerated lesion at 7-8 cm from the anal verge forming a pseudo-diverticular area with adjacent inflammatory polypoid mucosa that requires a differential diagnosis between a malignant rectal tumor, rectal solitary ulcer, or chronic inflammatory process (Figure 3.a.-3.c).



**Fig. 3.a.** Circumferential infiltrative ulcerated lesion



**Fig. 3.b.** Pseudo-diverticular area of the rectal lesion



**Fig. 3.c.** Inflammatory polypoid mucosal area of the rectal lesion

Considering the colonoscopy's results, which cannot provide a definite diagnosis in the absence of an pathological examination that takes a few days, there was suspicion of a lumbar malignant cutaneous tumor which was not further investigated. To check for a possible link between the two of them, a thoraco-abdomino-pelvic CT scan was performed, revealing a thickening of the inferior rectal wall with adjacent pseudo-diverticular aspects, which may correspond to a rectal neoplasm but should be interpreted in a clinical context with AP exam results reviewed. The scan also showed the lumbar cutaneous lesions described above correlating with the AP exam and surgical absence of uterus and ovaries.

The patient was transferred to a plastic surgery department for excision and biopsy of the lumbar tumor that revealed a multi-centric basal cell carcinoma developed in a non-sun-exposed area.

The pathological examination of the rectal biopsy sustained chronic proctitis.

Rectal bleeding stopped after cessation of Dabigatran, administration of oral hemostatic agent Etamsilat and supportive measures.

Three weeks after surgery, the patient had a cardiovascular re-evaluation to establish the possibility of anticoagulant therapy restoration. Laboratory exams also showed relapse of cystitis with *E. coli*.

In a patient with bleeding basal cell carcinoma and rectal bleeding due to chronic proctitis with unknown etiology, whose

symptoms manifested undergoing NOAC, it is important to note the bilateral absence of the ovaries revealed by an abdominal CT scan since only the post-partum hysterectomy 45 years ago was mentioned. Careful review of the anamnesis revealed the patient remembered that after her post-partum hysterectomy she followed RT in high doses but she could not provide any further information or any related medical document.

This was the key of diagnosis: RT as etiology for chronic proctitis, basal cell carcinoma and recurrent cystitis.

Anticoagulant therapy was restored with Apixaban 2.5 mg twice daily due to its lower gastrointestinal bleeding (GIB) risk. A six month follow up showed a good cardiovascular and GI outcome without any hemorrhagic incidents but with recurrent cystitis despite double the antibiotic therapy.

## Discussions

For decades now RT is broadly used to treat pelvic neoplasms and due to its remarkable improvements regarding dosage control and administration methods, the number of cancer survivors increased. Unfortunately, although life is prolonged, its quality is considerably diminished and patients experience acute and chronic effects recently acknowledged as PRD, a term encompassing radiation enteritis, radiation proctitis and radiation cystitis [1].

There are three accepted stages of PRD: acute, chronic, latent [1].

The acute phase is represented by acute inflammatory process limited to the mucosa occurring within the first 3 months of RT initiation. Symptoms consist of nausea, diarrhea, cramps, and rectal bleeding that disappear after RT cessation.

Consequences of chronic inflammatory status in PRD are directly proportional with the amount of used radiation and symptoms begin to develop within 6 months to 30 years after ionizing exposure, especially in the first two years. The process relies on progressive ischemia and fibrosis, including at the arteriolar intima level, leading to telangiectasia, the most frequent source for rectal bleeding in chronic proctitis. Other prominent features in chronic proctitis, a type of chronic PRD, are bowel dysmotility, fistulas, and chronic abscesses [1, 6].

The latent phase refers to secondary malignancies developed within or outside of the irradiated area, decades after RT, therefore tumor development should be included in the differential diagnosis of a patient who received RT. It is equally important to mention that not all patients receiving RT for pelvic tumors develop PRD. The reason is unclear, probably related to a variety of factors such as radiation type and dosage, site of tissue damage, comorbidities, and genetic factors [1, 6].

PRD requires further research and attention. Despite the fact that it is a predictable condition in patients receiving pelvic RT, there is a lack in the surveillance and management of these patients and the increasing burden of PRD diminishes survival. According to past data, the annual incidence of patients diagnosed with PRD is larger than the number diagnosed with Crohn's disease, yet the service provided for PRD are far less abundant [1, 7].

The case presented reflects the above, and its complexity results from unexpected complications not seen in theoretical examples. Despite multiple hospitalizations in varied medical services, RT is never registered because the patient never mentions it. In this case, diagnosis was incidental, based on symptoms triggered by NOAC therapy in a

fibrillation patient, the most common indication for anticoagulant in general population [8].

Developed as an alternative to traditional anticoagulants, NOAC rapidly gained worldwide usage thanks to its ease of oral administration without international normalized ratio monitoring. Despite their advantages there are also some restraints like the limited clinical experience, lack of validated laboratory testing of anticoagulant effect, caution needed in patients with renal impairment and the high cost of the product [9].

Randomized controlled studies have shown that NOACs have the same safety and efficacy profile as warfarin regarding stroke prevention and systemic embolus formation but they are also associated with increased risk of GIB, especially Dabigatran in 150 mg twice daily [9, 10]. Post-market data (RELYABLE study for Dabigatran and ROCKET-AF for Rivaroxaban) shows the increased risk for GIB in NOAC users is clinically relevant only in elderly patients, with comorbidities or with concurrent medication, especially with antiplatelets agents associated with Dabigatran [11-14]. It is also worth mentioning that GIB associated with Dabigatran use occurs from a source in the lower GI tract while GIB associated with warfarin, nonsteroidal anti-inflammatory drugs or antiplatelets agents come from the upper GI tract [9, 14]. These are supposed to be related to the incomplete absorption of NOAC in upper GI tract resulting in high availability of Dabigatran in the lower GI tract which affects the mucosa leading to bleeding, especially in the presence of lesions like erosions, angiodysplasia, telangiectasia or tumor angiogenesis [15, 16].

The macroscopic aspect of both rectal and lumbar lesions, abdominal CT scans (which do not exclude the possibility of a tumor), advanced age, and the sudden onset of concomitant bleeding gave rise to the idea of related malignant tumors, likely colorectal cancer with cutaneous metastasis, given the concept that anticoagulation may serve as a GI stress test, unmasking occult luminal GI tract neoplasm by inducing GI tract bleeding [9, 17]. AP exams revealing chronic proctitis, basal cell carcinoma that developed in a non-sun-exposed area and a bilateral ovariectomy





in a 35 year-old female with a presumed hemostatic hysterectomy invalidated the diagnosis and required a more careful anamnesis that finally clarified the case.

Cardiovascular status is just as important to mention since the main symptoms the patient addressed first was fatigue and dizziness. Permanent AF, asymptomatic VES associated with early onset of hypertension, autoimmune thyroiditis, and osteoporosis after hormonal deprivation demands complex medical treatment including permanent anticoagulation. Dabigatran cessation and supportive measures were enough to control the bleeding. According to the last European guideline for AF, which recommends a temporary pause on anticoagulants to control active hemorrhaging with very rare contraindications allowed for long term NOAC after a bleeding episode, we restarted anticoagulant therapy with Apixaban 2.5 mg twice daily due to its lower GIB risk, with a favorable outcome [4, 18].

Another element that sustains a PRD diagnosis is radiation cystitis suggested by re-occurring low urinary tract infections that require supplementary investigations by an urologist.

## Conclusions

In a patient with multiple chronic comorbidities, without major breakdowns, symptoms are seen after a necessary therapeutic action for an asymptomatic patient with AF. Independent evolution of two afflictions (chronic radiation proctitis and basal cell carcinoma), initially considered as both malignant and related because they were simultaneously triggered by the same factor (NOAC), turned up to share the same etiology: pelvic radiotherapy. This reflects the unpredictable development of a patient undergoing NOAC and the lack of consideration given to PRD. A careful anamnesis is as important as extensive paraclinical exams.

## Consent

Written informed consent was obtained from the patient for publication of this case report.

## Competing interests

The authors declare that they have no competing interests.

## References

1. Morris KA, Haboubi NY. Pelvic radiation therapy: Between delight and disaster. *World J Gastrointest Surg* 2015; 7(11):279-288.
2. Dörr W. Radiobiology of tissue reactions. *Ann ICRP* 2015; 44(1):58-68.
3. Do NL, Nagle D, Poylin VY. Radiation proctitis: current strategies in management. *Gastroenterol Res Pract* 2011; 2011:917941.
4. Kirchhof P, Benussi S, Kotecha D, et al. 2016 ESC Guidelines for the management of atrial fibrillation developed in collaboration with EACTS. *Eur Heart J* 2016; 37(38):2893-2962.
5. Deutsch D, Boustière C, Ferrari E, Albaladejo P, Morange PE, Benamouzig R. Direct oral anticoagulants and digestive bleeding: therapeutic management and preventive measures. *Therap Adv Gastroenterol* 2017; 10(6):495-505.
6. Vanneste BG, Van De Voorde L, de Ridder RJ, Van Limbergen EJ, Lambin P, van Lin EN. Chronic radiation proctitis: tricks to prevent and treat. *Int J Colorectal Dis* 2015; 30(10):1293-1303.
7. Denham JW, Hauer-Jensen M. Radiation induced bowel injury: a neglected problem. *Lancet* 2013; 382:2046-2047.
8. Short NJ, Connors JM. New oral anticoagulants and the cancer patient. *Oncologist* 2013; 19(1):82-93.
9. Desai JC, Chatterjee P, Friedman K, Aisenberg J. Incidence and clinical presentation of gastrointestinal bleeding in atrial fibrillation patients taking direct oral anticoagulants. *Am J Gastroenterol* 2016; 3:13-21.
10. Connolly SJ, Ezekowitz MD, Yusuf S, et al. Newly identified events in the RE-LY trial. *N Engl J Med* 2010; 363:1875-1876.
11. Connolly SJ, Wallentin L, Ezekowitz MD, et al. The long-term multicenter observational study of Dabigatran treatment in patients with atrial fibrillation (RELY-ABLE) Study. *Circulation* 2013; 128:237-243.
12. Manesh RP, Mahaffey KW, Garg J, et al. Rivaroxaban versus Warfarin in nonvalvular atrial fibrillation. *N Engl J Med* 2011; 365:883-891.



13. Farcas A, Bataga S, Cijevschi C, et al. Gastrointestinal endoscopy in patients on direct oral anticoagulants. a consensus paper of the Romanian Society of Gastroenterology and Hepatology. *J Gastrointestin Liver Dis* 2018; 27(2):179-187.
14. Eikelboom JW, Wallentin L, Connolly SJ, et al. Risk of bleeding with 2 doses of Dabigatran compared with Warfarin in older and younger patients with atrial fibrillation: an analysis of the randomized evaluation of long-term anticoagulant therapy (RE-LY) trial. *Circulation* 2011; 123:2363-2372.
15. Cheung KS, Leung WK. Gastrointestinal bleeding in patients on novel oral anticoagulants: Risk, prevention and management. *World J Gastroenterol* 2017; 23(11):1954-1963.
16. Blech S, Ebner T, Ludwig-Schwellinger E, Stangierand J, Roth W. The metabolism and disposition of the oral direct thrombin inhibitor, Dabigatran, in humans. *Drug Metab Dispos* 2008; 36(2):386-399.
17. Clemens A, Strack A, Noack H, et al. Anticoagulant-related gastrointestinal bleeding - could this facilitate early detection of benign or malignant gastrointestinal lesions? *Ann Med* 2014; 46:672-678.
18. Granger CB, Alexander JH, McMurray JJ, et al. Apixaban versus warfarin in patients with atrial fibrillation. *N Engl J Med* 2011; 365(11):981-992.

